

# Rarely Seen Benign Tumor of the Uterus, Angiolipoleiomyoma: A Case Report

Busra Demir Cendek<sup>1</sup>, Ayse Filiz Avsar<sup>2</sup>, Evrim Bostanci Ergen<sup>1</sup>, Huban Sibel Orhun Yavuz<sup>3</sup>,  
Rahime Bedir Findik<sup>4</sup>

<sup>1</sup>Dr. Nafiz Körez Sincan State Hospital, Department of Obstetrics and Gynecology, Ankara, Turkey

<sup>2</sup>Atatürk Training and Research Hospital, Department of Obstetrics and Gynecology, Ankara, Turkey

<sup>3</sup>Atatürk Training and Research Hospital, Department of Pathology, Ankara, Turkey

<sup>4</sup>Dr. Zekai Tahir Burak Training and Research Hospital, Department of Obstetrics and Gynecology, Ankara, Turkey

## ABSTRACT

**Background:** Angiolipoleiomyoma is benign mesenchymal masses composed of smooth muscles, mature adipose cells, and abnormal blood vessels. It is rarely diagnosed in uterine masses and its prevalence among benign uterine lesions is 0.06%.

**Case Report:** A 59-year-old woman with postmenopausal uterine angiolipoleioma.

**Conclusion:** We reported the rare case of angiolipoleiomyoma to remind gynecologists to keep in mind this unusual tumour during the management of uterine masses.

**Keywords:** Uterine diseases, chronic abdominal pain, leiomyoma, angiolipoleiomyoma

## ÖZ

Nadir görülen iyi huylu uterus kitlesi, anjiolipoleiomyom: Olgu sunumu

**Amaç:** Anjiolipoleiomyomlar düz kaslar, olgun yağ hücreleri ve anormal kan damarlarının birleşiminden oluşan iyi huylu mezenkimal kitlelerdir. Uterus kitlelerinde nadiren saptanır ve iyi huylu uterus lezyonlarında görülme prevalansı %0.06'dır.

**Olgu:** 59 yaşında postmenopozal kadında saptanan uterus anjiyolipoleiyomu.

**Sonuç:** Bu nadir görülen anjiyolipoleiyom olgusunu, jinekologlara uterin kitleleri değerlendirirken bu nadir tümörü akılda tutmaları gerektiğini hatırlatmak için sunduk.

**Anahtar kelimeler:** Uterus hastalıkları, kronik karın ağrısı, anjiolipoleiomyom

Received/Geleş tarihi: 24.09.2014 Accepted/Kabul tarihi: 20.04.2015



**Address for Correspondence/Yazışma Adresi:** Evrim Bostanci Ergen, Dr. Nafiz Körez Sincan State Hospital, Department of Obstetrics and Gynecology, Ankara, Turkey  
**Phone/Telefon:** +90-505-617-9623 **E-mail/E-posta:** evrimbostanc666@gmail.com

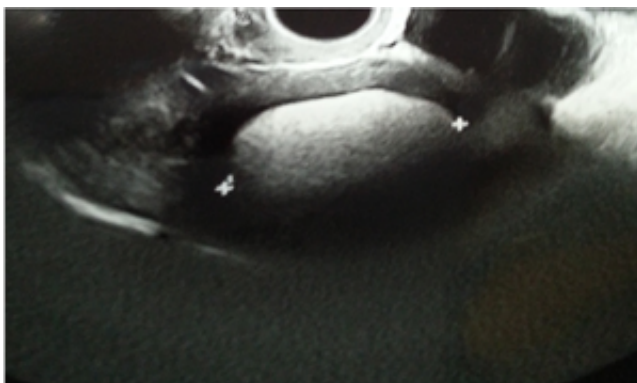
**Citation/Atrf:** Demir-Cendek B, Avsar AF, Bostanci-Ergen E, Orhun-Yavuz HS, Bedir-Findik R. Rarely seen benign tumor of the uterus, angiolipoleiomyoma: a case report. Bakırköy Tıp Dergisi 2018;14:142-5. <https://doi.org/10.5350/BTDMJB.20140924083104>

## INTRODUCTION

The angiolipoleiomyoma (ALLM), a benign mesenchymal tumor, is composed of smooth muscle, mature adipose tissues, and abnormal blood vessels. The tumor mostly identified in the renal tissues is usually accompanied by tuberous sclerosis. Approximately 69%- 80% of patients with this disease have a concurrent ALLM (1). The incidence of ALLM has been reported 0.2% in women in general population without tuberous sclerosis (2). The ALLM of the uterus is a rarely seen benign mixed mesenchyme tumor with a prevalence of 0.06% among benign uterine lesions (3). We report a case of an angiolipoleiomyoma of the uterus of a 59 year old postmenopausal woman.

## CASE REPORT

A 59 year old postmenopausal patient (gravity 6, parity 4, abortion 1) admitted to our hospital with a chronic lower abdominal pain. She had the history of appendectomy, left ovarian cystectomy, subtotal thyroidectomy, and had surgical resection of meningioma. She did not describe any chronic disease rather than hypertension. There were no significant diseases detected in the family history. Gynecological bimanual examination revealed the large uterine mass without having any adnexal pathology. Transvaginal sonography showed an anteverted uterus with a 75x61 mm brightly hyperechogenic solid mass located posterior wall of the uterus resembling myelolipoma (Figure 1). Both of the ovaries were observed as normal in

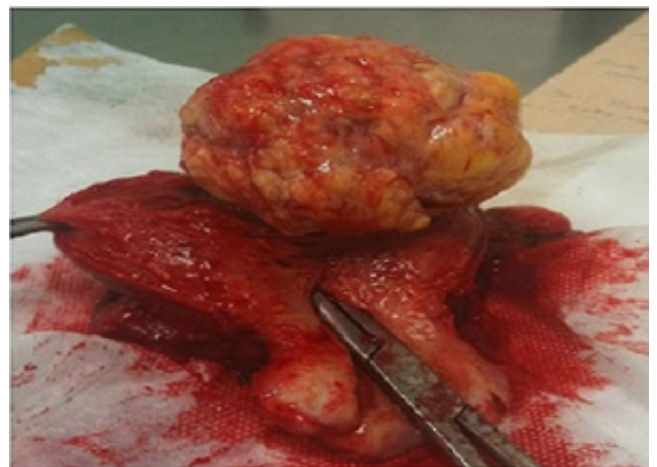

**Figure 1:** Brightly echogenic solid leiomyomatous mass with 75x61 mm size located on the posterior wall of the uterus, which detected by transvaginal sonography

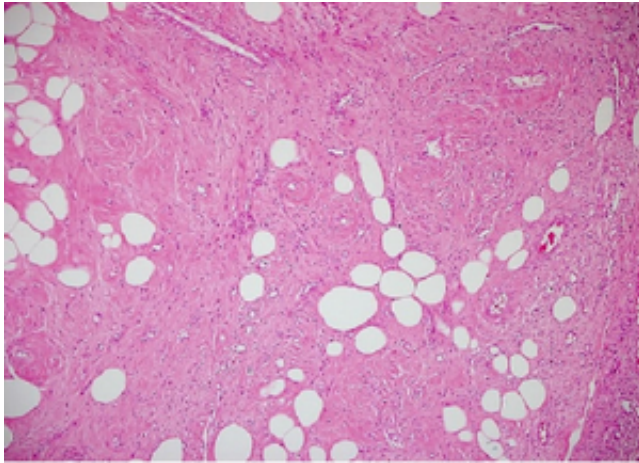
the ultrasound imaging. Cervical cytology of the patient was resulted as normal, and no increases in the preoperative serum tumor markers for the mass were observed in the patient.

Magnetic resonance imaging (MRI) examination of the abdomen confirmed smoothly rounded hypodense heterogeneous mass measuring 60x54 mm in fat suppressed (FS) sequences and hyperdense minimally heterogeneous lesion in T1 and T2-weighted sequences. This lesion showed heterogeneous enhancement on the contrast-enhanced MRI similar to the myelolipoma.

The patient underwent total abdominal hysterectomy and bilateral salpingo-oophorectomy on January 30, 2013 with an initial diagnosis of uterine mass. Intramural fibroid like mass with an approximately 6x6 cm in diameter arising from the posterior wall of the uterus was visualized intraoperatively. Considerable enlargement of the uterine size was seen in the operation. Bilateral ovaries and salpinx were detected as normal (Figure 2). Uterus together with the lesion, tuba uterine and ovaries were excised. All tissues obtained from the operation were sent for the pathological evaluation. The cut surfaces of the tumor revealed a marked gray, pink and brown discoloration suggesting mottling appearance. Necrosis and hemorrhage were barely seen in the lesion. Hematoxylin-eosin-stained sections of the lesion revealed the adipose tissue and blood vessels between the muscle bundles. The pathological examination has resulted in ALLM diagnose (Figure 3). The patient continued routine follow up visits after the operation.



**Figure 2:** The fibroid-like mass approximately 6x6 cm in diameter that excised from the posterior wall of the uterus



**Figure 3:** The adipose tissue and blood vessels between the muscle bundles, revealed by hematoxylin-eosin-stained section

## DISCUSSION

The term of ALLM is quite controversial. These lesions are described as hamartoma (4), lipoleiomyoma (3) and angiolipoleiomyoma (5) in the literature. ALLMs are generally found in the hepatorenal region and they are barely seen in the uterus. There are scarce cases related to uterine ALLM described in the literature (4,5).

The uterine angiolipomas show the histological similarities to the renal angiolipomas (6). However, unlike renal ALLM, uterine ALLM is not associated with tuberous sclerosis and HMB-45 antigens (7). The patient mentioned in this study didn't have any co-existing disease such as tuberous sclerosis related to tumors as in renal ALLMs. ALLM is accepted as a benign lesion of the uterus since no reported cases regarding aggressive postoperative courses of ALLM are described in the literature (6). Clinical findings of ALLM do not support significant differences between ALLM and myomas (7). Patients usually suffer from chronic abdominal or pelvic pain, menorrhagia, urinary incontinence and pelvic organ prolapse. Patients can also be totally asymptomatic regarding this tumor, and this mass can be detected by chance during the routine gynecological visits (7). In this case report our patient demonstrated long lasting lower abdominal pain.

Using the sonography in addition to computerized tomography and MRI in terms of diagnosing ALLM may help confirm the diagnosis preoperatively (8). In addition to

computerized tomography and MRI, the sonography may help confirm the diagnosis preoperatively in terms of ALLM (8). Most of the ALLMs are found in the uterine corpus (9) and location at the cervix and lower uterine segment follow this area. ALLMs usually tend to grow in subserosal or intramural fashion in the uterus (9). We used MRI to describe the mass in uterus.

The mean tumor size is approximately 8.4 cm in diameter, but this measurement can vary between 2 to 16 cm in diameter. Although these tumors are usually surrounded by a pseudocapsule they can demonstrate an infiltrative growing pattern too (9). ALLMs can be presented as solid or soft masses according to the amounts of contents (smooth muscle, fat tissue and vascular structures) they have. ALLMs exhibit morphological manifestations of hamartomas. Although they have consisted of three mesenchymal elements as mature adipose tissue, smooth muscle cells, and abnormal blood vessels, there is no consensus on the criteria of diagnosing ALLM based on the proportions of these three components (7). ALLMs contain heterogeneous morphological subtypes. They can become indistinguishable from vascular leiomyomas, lymphangioleiomyomas and epithelioid tumors by mimicking them completely (10).

In the present case, pathological evaluation of the tumor clearly demonstrated the three components of ALLM. Especially identifying abnormal distorted and twisted blood vessels with thickened walls among smooth muscle bundles were pathognomonic of ALLM as described in the literature (7). In our case, hematoxylin-eosin-staining identified the adipose tissue and blood vessels between the muscle bundles of the specimen. There is scarce information about the immunohistochemical staining of ALLM in the literature (7) since most of the uterine ALLM case reports were published before the 1990s when immunohistochemical staining was not in routine use in the medical area. As far as we know, these unique tumors show desmin and alpha smooth muscle actin positive and HMB-45 negative features (7). Although a combination of ultrasonography, BT and MRI can help improve the preoperative diagnosis of lipomatous uterine tumors, the pathological evaluation of the tumour brings about the final diagnosis. As in the present case, hysterectomy is the preferred method of the treatment.

In this article, we reported the rare case of ALLM to

remind gynecologists to keep in mind this unusual tumor during the management of uterine masses. The aim of this case report is to introduce this infrequently seen uterine tumor to gynecologist's attention, hereby this rare tumor can be kept in mind while making a differential diagnosis of uterine masses.

**Informed Consent:** Informed consent was obtained.

**Author contributions:** Follow up of the case - R.B.F., B.D.C., A.F.A., H.S.O.Y.; Literature review - R.B.F., E.B.E., H.S.O.Y., B.D.C.; Manuscript writing - E.B.E., B.D.C., R.B.F., A.F.A.; Manuscript review and revision - H.S.O.Y., E.B.E., A.F.A.

**Conflict of Interest:** Authors declared no conflict of interest.

**Financial Disclosure:** Authors declared no financial support.

## REFERENCES

1. Sooriakumaran P, Gibbs P, Coughlin G, et al. Angiomyolipomata: challenges, solutions, and future prospects based on over 100 cases treated. *BJU Int* 2010;105(1):101-6. [\[CrossRef\]](#)
2. Fujii Y, Ajima J, Oka K, Tosaka A, Takehara Y. Benign renal tumors detected among healthy adults by abdominal ultrasonography. *Eur Urol* 1995; 27: 124-7. [\[CrossRef\]](#)
3. Shintaku M. Lipoleiomyomatous tumors of the uterus: a heterogeneous group? Histopathological study of five cases. *Pathol Int* 1996;46(7):498-502. [\[CrossRef\]](#)
4. McKeithen SW, Shinner J, Michelsen J. Hamartoma of the uterus, report of a case. *Obstet Gynecol* 1964;24(2):231-4.
5. Sieinski W. Lipomatous neometaplasia of the uterus: report of 11 cases with discussion of histogenesis and pathogenesis. *Int J Gynecol Pathol* 1989;8(4):357-63. [\[CrossRef\]](#)
6. Huang PC, Chen JT, Ho WL. Clinicopathologic analysis of renal and extrarenal angiomyolipomas: report of 44 cases. *Chin Med J (Taipei)* 2000;63(1):37-44.
7. Ren RL, Wu HHJ. Pathologic quiz case: a 40-year-old woman with an unusual uterine tumor. Uterine angiolipoleiomyoma with focal atypical leiomyoma. *Arch Pathol Lab Med* 2004;128(2):e31-2.
8. Braun HL, Wheelock JB, Amaker BH, Seeds JW. Sonographic evaluation of a uterine angiolipoleiomyoma. *J Clin Ultrasound*. 2002;30(4):241-4. [\[CrossRef\]](#)
9. Yaegashi H, Moriya T, Soeda S, Yonemoto Y, Nagura H, Sasano H. Uterine angiomyolipoma: case report and review of the literature. *Pathol Int* 2001;51(11):896-901. [\[CrossRef\]](#)
10. Kim NR, Suh YL. Renal angiomyolipoma with vascular leiomyomatous features: a case report. *Korean J Pathol* 2002;36(5):353-6.