



# A Rare Case: Ruptured Ectopic Pregnancy with Contralateral Adnexal Torsion

Murat Ekin, Cihan Kaya, Huseyin Cengiz, Levent Yasar, Keziban Dogan

*Bakırköy Dr Sadi Konuk Training and Research Hospital, Clinic of Gynecology and Obstetrics, İstanbul*

## ÖZET

*Nadir bir olgu: Karşı taraf adneksiyal torsiyonla birlikte görülen rüptüre ektopik gebelik*

Ektopik gebelik ve ovaryan torsiyon jinekolojik aciller olarak bilinirler. Bu yaşama tehdit eden durumların birlikteliği nadirdir. Erken tanı ve doğru yönetimle gelecekteki doğurganlık yeteneği ve yaşam korunabilir. Bu makalede spontan konsepsiyon sonrası rüptüre ektopik gebelik ve aynı anda karşı taraf over torsiyonu olan bir hastayı sunmaktayız.

**Anahtar kelimeler:** Adneksiyal torsiyon, aciller, tubal gebelik

## ABSTRACT

*A rare case: ruptured ectopic pregnancy with contralateral adnexal torsion*

Ectopic pregnancy and ovarian torsion both are known as gynecologic emergencies. Coexistence of these life-threatening conditions are rare. Early detection and prompt management can save life and future fertility. In this report we presented a unique case of ruptured tubal ectopic pregnancy with concomitant contralateral side ovarian torsion in a patient with spontaneous conception.

**Key words:** Adnexal torsion, emergencies, tubal pregnancy

**Bakırköy Tıp Dergisi 2015;11:29-32**

## INTRODUCTION

Ectopic pregnancy is described as the gestational sac is implanted outside the uterus. The prevalence of ectopic pregnancy is %2 of all pregnancies in the United States, and it is one of the leading causes of pregnancy related deaths during first trimester in women of childbearing age (1). Ovarian torsion is an infrequent but significant cause of lower abdominal pain in women. It is defined as partial or complete rotation of ovarian vascular pedicle and causes obstruction to venous outflow and arterial inflow and it is the 5th common gynecological emergency with reported prevalence of %2.7 (2,3). Ovarian torsion can occur women in all ages but most cases occur in the early reproductive years. Co-existence of ectopic pregnancy and ovarian torsion is rare and there is only a few case reports in the literature (4,5).

Yazışma adresi / Address reprint requests to: Cihan Kaya  
Bakırköy Dr Sadi Konuk TRH, Clinic of Gynecology and Obstetrics, İstanbul  
Telefon / Phone: +90-212-414-5059

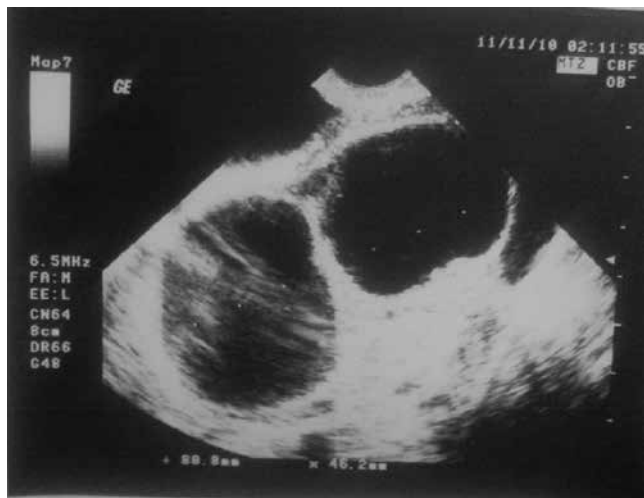
Elektronik posta adresi / E-mail address: drcihankaya@gmail.com

Geliş tarihi / Date of receipt: 11 Kasım 2011 / November 11, 2011

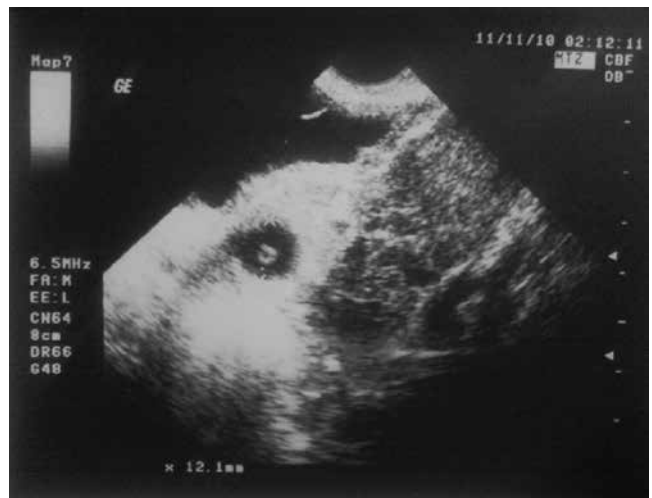Kabul tarihi / Date of acceptance: 29 Şubat 2012 / February 29, 2012

## CASE REPORT

A 26-year-old gravida 1 para 1 woman presented to the Emergency Department at our hospital with severe bilateral lower quadrant pain. The pain was constant with episodes of sharp intermittent pain. Her last menstrual period was approximately four weeks before the presentation. She reported nausea with episode of emesis on the evening of admission. The patient had regular menstrual cycles occurring every 28 days and lasting approximately 5 days. She had history of pelvic inflammatory disease and smoking habit. She had cesarean section one year ago because of twin pregnancy and reported coitus interruptus for contraception. She was normotensive and had rhythmic normal pulse rate. Physical examination revealed bilateral lower quadrant rebound and tenderness. The vagina and the cervix were clear in her examination with speculum. Bimanual examination revealed bilaterally tender adnexae, and a palpable right adnexal mass. Transvaginal pelvic ultrasound revealed homogeneous endometrial stripe measuring 15 mm, biloculated right ovarian mass which measured 80x46



**Figure 1:** Bilocolated right adnexal mass with dimension of 80 x 46 mm.



**Figure 2:** Ectopic focus with gestational sac and yolk sac and organised coagulum at the left adnexa .

mm (Figure 1), ectopic focus with gestational and yolk sac which measured 12 mm in the left adnexa (Figure 2) and a mild amount of heterogeneous free fluid in the cul-de-sac. The Doppler sonography revealed no arterial and venous blood flow in the right ovarian mass. The patient's hemoglobin and hematocrit were 12.1 g/dL and 37.3%, respectively. Her white blood cell count was 12,200/mL with no left shift, B-hCG was 2356 IU/L. Emergent laparotomy was performed for acute abdominal pain. Approximately 250 mL of blood and clots was noted in the cul-de-sac. Inspection of the left adnexa revealed an ampullary ectopic pregnancy with evidence of rupture through the medial antimesenteric border. There was active bleeding noted through the site of rupture as well as blood and clot protruding from the ampullary part of the fallopian tube. The left ovary appeared normal. Right salpingectomy was performed. A bilocolated right adnexal mass with measure of about 90x60 mm was noted. This was the right ovary and fallopian tube, which were ischemic, edematous, and torsed three times about the axis of the infundibulopelvic and uteroovarian ligaments. The right ovary and tube were immediately detorsed. The ovary and tube appeared to rapidly regain normal perfusion, as evidenced by their pink color within approximately 2 minutes. The right ovary was also initially noted to have a 50x40 mm complex cyst which appeared to be consistent with a hemorrhagic corpus luteum. Right ovarian cystectomy performed and ovarian tissue restored by primer continue suturing

subsequently and no active bleeding was noted. The patient's postoperative course was uncomplicated and she was discharged to home on the second postoperative day. She had no further episodes of pain. Pathology revealed an implantation site and chorionic villi in the right fallopian tube. B-hCG levels were followed on an outpatient basis until they were at <6 IU/L to confirm complete resolution of the ectopic pregnancy.

## DISCUSSION

Adnexal torsion and ruptured ectopic pregnancy both represent gynecologic surgical emergencies. These events are relatively rare, and extremely rare when occurring in combination. Recognized risk factors for ovarian torsion include adnexal masses, enlargement of the corpus luteum cysts, ovarian hyperstimulation, and pregnancy. In fact, %12-%18 of ovarian torsion cases occur during pregnancy (6). As we detected in our case there is a right-sided predominance to ovarian torsion. Two theories have been proposed in an attempt to explain this finding. One proposes that the left side is protected from torsion, because it has less mobility owing to the sigmoid colon. The second theory suggests that the right-sided predominance is due to the different venous drainage systems of the two ovaries (7). Adnexal torsion consists of total or partial rotation of the adnexa around its vascular axis. Venous and

lymphatic blockade, followed by arterial-flow stasis, may lead to massive congestion of ovarian stroma, hemorrhagic infarction, gangrene and/or hemorrhagic necrosis (8). Symptoms are nonspecific and the classical presentation is localized lower abdominal pain and tenderness and peritoneal signs. According to Shaddinger et al. patients with torsion had abdominal pain (100%), vomiting (85%), leukocytosis (56%) and (18%) elevated body temperature (9). Imaging studies may help in diagnosis. The Doppler sonography correctly diagnosed torsion in only 40% of surgically confirmed cases. Although Doppler in that series was not very sensitive, it was highly specific. All cases with absent or decreased Doppler flow had surgically confirmed ovarian torsion but physicians should be remembered that normal flow by Doppler sonography does not rule out ovarian torsion, and the diagnosis of ovarian torsion should be based on clinical suspicion (10). Previously, radical salpingo-oophorectomy, without prior detorsion has been performed due to concern about embolus migration from the twisted pedicle. No thromboembolic complication secondary to detorsion has been reported during recent times and Chapron et al. and Cohen et al. suggest that conservative treatment is warranted to preserve fertility, even for adnexa that initially appear non-viable, and purple or black in coloration (11,12). Ovarian cystectomy and detorsion of the adnexa appear to be the most effective treatment methods for women who desire further childbearing.

Approximately 1-2% of all pregnancies in Europe and the USA are ectopic and in the Western world tubal ectopic pregnancy remains the most common cause of maternal mortality in the first trimester of pregnancy (13). In spite of the high occurrence of ectopic pregnancy, early detection can be difficult. The initial diagnosis of ectopic pregnancy is based on physical examination, medical history, B-hCG value and sonographic findings. The quantitative B-hCG levels <1500 mIU/ml, combined with transvaginal ultrasound has been proposed in diagnosing ectopic pregnancy with 100% sensitivity and 99.9% specificity (14). In our case PID, smoking and previous cesarean section histories were risk factors and may predispose for ectopic pregnancy. As for treatment options methotrexate or expectant management are now considered for hemodynamically stable patients with ectopic pregnancy. Laparoscopy or laparotomy is suggested in hemodynamically unstable patients.

In conclusion ruptured ectopic pregnancy and ovarian torsion both are gynecological emergencies. Patients usually presents with nonspecific symptoms like lower abdominal pain, vomiting and leukocytosis. In emergency department physicians should be aware about gynecological emergencies and early diagnosis is important in both ectopic pregnancy and ovarian torsion, especially for preserving future fertility and ovarian reserve, but the most important for preventing morbidity and mortality in women of reproductive age.

## REFERENCES

- Houry DE, Salhi BA. Acute complications of pregnancy. In: Marx JA (Ed). Rosen's Emergency Medicine: Concepts and Clinical Practice. 7th ed. Philadelphia, Pa: Mosby Elsevier; 2009: chap. 176.
- Chang HC, Bhatt S, Dogra VC. Pearls and pitfalls in diagnosis of ovarian torsion. Radiographic 2008; 28: 1355-1368.
- Michele B, Giovanni S, Palo T, et al. Adnexal torsion. Ultrasound Clin 2008; 3: 109-119.
- Andrea JD, Donald BM, Claudio AB. Ruptured ectopic pregnancy with contralateral adnexal torsion after spontaneous conception. Fertil Steril 2008; 90: e1-e3.
- Hun-Shan P, Lee-Wen H, Chun-Yi L, et al. Ovarian pregnancy torsion. Arch Gynecol Obstet 2004; 270: 119-121.
- Chambers JT, Thiagarajah S, Kitchin JD. Torsion of the normal fallopian tube during pregnancy. Obstet Gynecol 1979; 54: 487-490.
- Peña JE, Ufberg D, Cooney N, Denis A. Usefulness of Doppler sonography in the diagnosis of ovarian torsion. Fertil Steril 2000; 73: 1047-1050.
- Graif M, Itzchak Y. Sonographic evaluation of ovarian torsion in childhood and adolescence. Am J Roentgenol 1988; 150: 647-649.
- Shaddinger LL, Andretti RF, Kurian RL. Preoperative sonographic and clinical characteristics predictors of ovarian torsion. J Ultrasound Med 2008; 27: 7-13.
- Lee EJ, Kwon HC, Joo HJ, Suh JH, Fleischer AC. Diagnosis of ovarian torsion with color Doppler sonography: depiction of twisted vascular pedicle. J Ultrasound Med 1998; 17: 83-89.
- Zweizig S, Perron J, Debra M, Daniel R. Conservation management of adnexal torsion. Am J Obstet Gynecol 1993; 168: 1791-1795.

A rare case: Ruptured ectopic pregnancy with contralateral adnexal torsion

12. Chapron C, Capella-Allouc S, Dubuisson JB. Treatment of adnexal torsion using operative laparoscopy. *Hum Reprod* 1996; 11: 998-1003.
13. Varma R, Gupta J. Tubal ectopic pregnancy. *BMJ Clin Evid* 2009; Pii: 1406.
14. Counselman FL, Shaar GS, Heller RA, et al. Quantitative B-hCG levels less than 1000 mIU/ml. in patients with ectopic pregnancy: pelvic ultrasound still useful. *J Emerg Med* 1988; 16: 699-703.