



# Spontaneous Perforation of Pyometra; a Rare Cause of Acute Abdomen: Report of a Case

Süleyman Bozkurt<sup>1</sup>, Tuba Atak<sup>2</sup>, Halil Coşkun<sup>1</sup>

<sup>1</sup>Bezmialem Vakıf University, Faculty of Medicine, Department of General Surgery, İstanbul

<sup>2</sup>İstanbul Medeniyet University, Göztepe Training and Research Hospital, Department of General Surgery, İstanbul

## ÖZET

*Spontan pyometra perforasyonu; nadir bir akut karın sebebi: Olgu sunumu*

Pyometra uterus kavitesi içinde pürülan materyal bulunmasıdır. Bu yazıda gastrointestinal perforasyon olarak düşünülen, akut batına sebep olan perfore pyometra olgusu sunulmaktadır. Altmış sekiz yaşında kadın hasta ani başlayan alt karın ağrısı nedeni ile acil servise başvurdu. Düz karın grafisinde peritoneal kavitede serbest hava mevcuttu. Laparotomide 12x7x4 cm perfore uterus tespit edildi. Histerektomi, bilateral salpingooferektomi uygulandı. Postoperative period sorunsuz geçen hasta 13. günde taburcu edildi. Nadir olmasına rağmen akut abdomen bulguları olan yaşlı kadın hastalarda pyometra perforasyonu ayrıntı tanıda düşünülmelidir.

**Anahtar kelimeler:** Pyometra, akut karın

## ABSTRACT

*Spontaneous perforation of pyometra; a rare cause of acute abdomen: report of a case*

Pyometra is defined as pooling of purulent material in the uterine cavity. We report a perforated pyometra presented with acute abdomen who was initially diagnosed as gastrointestinal perforation. A 68 year old woman was admitted as an emergency having developed sudden lower abdominal pain. Plain abdominal X-ray revealed free air in the peritoneal cavity. At laparotomy, enlarged perforated uterus of 12x7x4 cm in size was revealed. Hysterectomy and bilateral salpingoophorectomy was performed. Postoperative period was uneventful. Patient was discharged at thirteenth day. Although rare, perforation of pyometra should be considered in the differential diagnosis in an elderly woman with an acute abdomen.

**Key words:** Pyometra, acute abdomen

Bakırköy Tıp Dergisi 2016;12:44-46

## INTRODUCTION

Pyometra is defined as pooling of purulent material in the uterine cavity and occurs when the natural drainage of the uterine cavity is compromised. It develops gradually and progresses to enlarge the uterine size. This enlargement may causes degenerative changes that may lead to sloughing of uterine wall with subsequent spillage of contents into the abdominal cavity. This leads to signs and symptoms of acute abdomen, which require abdominal exploration. We report here a perforated pyometra presented with

acute abdomen who was initially diagnosed as gastrointestinal perforation.

## CASE REPORT

A 68 year old hypertensive, type II diabetic woman was admitted as an emergency having developed sudden lower abdominal pain 10 hours previously. The pain had become progressively worse in time and accompanied with nausea and vomiting. On examination she had diffuse guarding and tenderness. The rectal examination was normal. The temperature was 38.2°C, pulse rate was 106/min, blood pressure was 120/70 mmHg and WBC count was 22,400/mm<sup>3</sup>. Plain abdominal X-ray revealed free air in the peritoneal cavity (Figure 1). As viscus perforation was suspected a gynecological examination was not performed. A laparotomy was done through a midline upper incision. Copious amounts of pus (>1000 ml) were found in the coelomic cavity, but

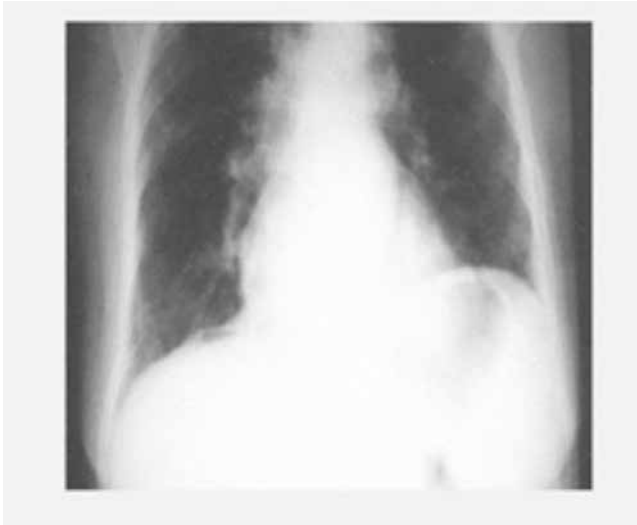
Yazışma adresi / Address reprint requests to: Dr. Tuba Atak  
İstanbul Medeniyet University, Göztepe Training and Research Hospital,  
General Surgery Clinic, İstanbul

Telefon / Phone: +90-505-600-5413

Elektronik posta adresi / E-mail address: drtuba81@yahoo.com

Geliş tarihi / Date of receipt: 24 Eylül 2012 / September 24, 2012

Kabul tarihi / Date of acceptance: 10 Şubat 2013 / February 10, 2013



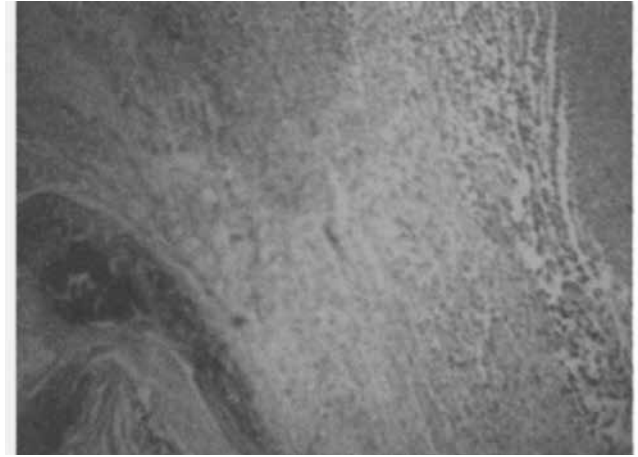
**Figure 1:** Free air under the diaphragm

no gastrointestinal perforation revealed. The exploration of the lower abdomen with caudally extended midline incision revealed soft and enlarged uterus of 12x7x4 cm in size perforated in the fundus. The macroscopic examination of the uterus and adnexae were normal. After intraoperative gynecologic consultation, hysterectomy and bilateral salpingo-oophorectomy was performed with peritoneal lavage and drainage. Postoperatively antibiotic treatment with cefoperazone 1 gram four times a day and metronidazole 0.5 gram three times a day was started. After three days in intensive care unit she was transferred to the surgery unit. Her condition improved postoperatively and on the thirteenth postoperative day the patient was discharged uneventfully.

A culture from the peritoneal pus grew *E. Coli* and *Bacteroides fragilis* which were sensitive to the antibiotics given. Histologic examination of the resected specimen showed chronic cervicitis and nabothian cysts on the cervix. The adnexae were atrophic. The entire endometrium showed gross and microscopic evidences of acute inflammatory process; which in some parts found to be gangrenous type. There was no evidence of malignancy (Figure 2).

## DISCUSSION

A pyometra is a collection of pus distending the uterine cavity. Pyometra is an uncommon condition with an incidence of less than 1% in gynaecologic patients (1).



**Figure 2:** Microscopic examination of the endometrium revealing dense inflammatory cell infiltration without evidence of malignancy (H&E, X 40)

However, it is more common in elderly (13.6%), post-menopausal women usually with concurrent medical conditions (2,3). A spontaneous perforation of pyometra and subsequent diffuse peritonitis is rare, with the incidence being about 0.01-0.05% (4).

Although the etiology of pyometra is varied, the common pathology to all causes is occlusion of the cervical canal. Pyometra with or without symptoms (vaginal discharge, vaginal bleeding, abdominal pain) is relatively common in patients with primary uterine malignancies and with secondary tumors that spread by local invasion (3,5). Other conditions disposing to pyometra are vaginal repair operations, puerperal infections, forgotten intrauterine device, genital tuberculosis, benign tumors of the cervix, atrophic cervicitis, previous radiation of pelvic organs, extragenital cancers invading cervix and in vitro fertilization. Occasionally no underlying disease can be found (3,4,5).

Establishing a preoperative diagnosis is difficult for pyometra because many patients present with non specific symptoms (1,6). Only when it is complicated it become obvious.

The treatment of pyometra is cervical dilation and drainage of the collection, with regular monitoring to detect recurrent or persistent disease (7,8). Increasingly interventional radiology may offer an alternative to surgery. Antibiotics are only necessary if there is evidence of invasive infection. Hysterectomy is also advisable as a definitive treatment choice. The treatment of the perforated pyometra is hysterectomy, peritoneal lavage, drainage and antibiotherapy covering both anaerobic

and aerobic organisms (4,8). Early diagnosis of pyometra before perforation can avoid surgical exploration and decrease morbidity and mortality.

Pyometra is a serious medical condition because of its association with malignant disease and danger of spontaneous perforation of uterus that carries significant morbidity and mortality. Early diagnosis is very important to start immediate treatment because these patients are elderly, in poor general condition, and require prompt intervention (7).

Spontaneous perforated pyometra is a rare entity, in most cases it has been diagnosed intraoperatively. Features on examination may be indistinguishable from other causes of peritonitis with rigidity, tenderness rebound and guarding (2). In perforated pyometra, other causes of acute abdomen will need to be ruled out. For

this magnetic resonance imaging and computed tomography are important diagnostic tools. But unfortunately perforated pyometra is mostly diagnosed during exploratory laparotomy (6,8).

Prognosis will depend both on the underlying cause (e.g. malignancy) and whether or not spontaneous perforation has occurred. Prompt recognition and treatment of the condition improves the prognosis considerably (2). The cases not associated with malignancy have better prognosis as expected. This is based on the fact that 73% of nonmalignant cases had a favorable prognosis for survival whereas only 33% of malignant cases had a favorable prognosis for survival (7).

Although rare, perforation of pyometra should be kept as one of the differential diagnosis in an elderly woman with an acute abdomen.

## REFERENCES

1. Geranpayeh L, Fadaei-Araghi M, Shakiba B. Spontaneous uterine perforation due to pyometra presenting as acute abdomen. *Infect Dis Obstet Gynecol* 2006; 2006: 60276.
2. Batukan C, Özçelik B, Müderris II. Spontaneous perforation of a pyometra presenting as generalized peritonitis: a case report. *Turkiye Klinikleri J Gynecol Obst* 2006; 16: 36-38.
3. Yıldızhan B, Uyar E, Şişmanoğlu A, Güllüoğlu G, Kavak ZN. Spontaneous perforation of pyometra: a case report. *Infect Dis Obstet Gynecol* 2006; 2006: 26786.
4. Li CH, Chang WC. Spontaneous perforated pyometra with an intrauterine device in menopause: a case report. *Jpn J Infect Dis* 2008; 61:477-478.
5. Majd HS, Watermeyer S, Ismail L. Pyometra presenting in conjunction with bowel cancer in a post-menopausal woman: a case report. *Cases Journal* 2008; 1: 24.
6. Karamercan A, Deniz H, Biri A, Aytaç B. Pneumoperitoneum caused by perforation of pyometra without malignancy. *Gazi Med J* 2006; 17: 185-187.
7. Chan LY, Yu VSY, Ho LC, Lok YH, Hui SK. Spontaneous uterine perforation of pyometra. A report of three cases. *J Reprod Med* 2000; 45: 857-860.
8. Lien WC, Ong AW, Lai TI, Wang HP. Pyometra: a potentially lethal differential diagnosis in older women. *Am J Emerg Med* 2010; 28: 103-105.